



**Review Article**

**Heavy-Chain Diseases and Myeloma-Associated Fanconi Syndrome: an Update**

Roberto Ria, Franco Dammacco and Angelo Vacca.

Department of Biomedical Sciences and Human Oncology, Section of Internal Medicine, University of Bari “Aldo Moro” Medical School, Bari, Italy.

**Competing interests:** The authors have declared that no competing interests exist.

**Abstract.** The heavy chain diseases (HCDs) are rare B-cell malignancies characterized by the production of a monoclonal immunoglobulin heavy chain without an associated light chain. There are three types of HCD, defined by the class of immunoglobulin heavy chain produced: IgA ( $\alpha$ -HCD), IgG ( $\gamma$ -HCD), and IgM ( $\mu$ -HCD). Alpha-HCD is the most common and usually occurs as intestinal malabsorption in a young adult from a country of the Mediterranean area. Gamma- and  $\mu$ -HCDs are rarer and associated with a B-cell non-Hodgkin lymphoma that produces an abnormal Ig heavy chain. These patients may occasionally be diagnosed with a monoclonal gammopathy of undetermined significance (MGUS). Fanconi syndrome, on the other hand, can be primary (inherited) or secondary (acquired). The only exception to this rule is the idiopathic form. Adult acquired Fanconi syndrome can be a rare complication of a monoclonal gammopathy. At diagnosis, most patients have an MGUS or smoldering multiple myeloma, with renal failure and evidence of osteomalacia. During follow-up, patients can develop an end-stage renal disease. Chemotherapy provides little benefit on renal function.

**Keywords:** B-cell malignancies, Fanconi syndrome, Heavy chain disease, Monoclonal gammopathy, Multiple myeloma.

**Citation:** Ria R., Dammacco F., Vacca A. Heavy-chain diseases and myeloma-associated Fanconi syndrome: an update. *Mediterr J Hematol Infect Dis* 2018, 10(1): e2018011, DOI: <http://dx.doi.org/10.4084/MJHID.2018.011>

**Published:** January 1, 2018

**Received:** October 5, 2017

**Accepted:** December 23, 2017

This is an Open Access article distributed under the terms of the Creative Commons Attribution License (<https://creativecommons.org/licenses/by-nc/4.0>), which permits unrestricted use, distribution, and reproduction in any medium, provided the original work is properly cited.

Correspondence to: Roberto Ria, M.D., [www.orcid.org/0000-0002-1515-0090](http://www.orcid.org/0000-0002-1515-0090). Department of Biomedical Sciences, Section of Internal Medicine, University of Bari “Aldo Moro” Medical School, Polyclinic, Piazza Giulio Cesare 11, I-70124 Bari, Italy. Phone: +39-080-5593106, fax: +39-080-5593106; e-mail: [roberto.ria@uniba.it](mailto:roberto.ria@uniba.it)

**Introduction.** Heavy chain diseases (HCDs) are a group of three rare B-cell neoplasms that are clinically and morphologically distinct from one another, but have in common the production of an abnormal immunoglobulin (Ig) heavy chain incapable of binding light chains (LCs). The altered heavy chains contain deletions, insertions, and point mutations that are acquired during somatic hypermutation. These structural abnormalities typically result in loss of a large portion of the constant-1 (CH1) domain of the Ig heavy chain molecule responsible for LC binding, with different effects on the variable (V), diversity (D), and joining (J) regions.<sup>1-3</sup>

In the absence of an associated LC, the CH1 domain of the regular heavy chain binds to heat-shock protein 78 (HSP78) and undergoes degradation in the cell proteasome compartment. Regular heavy chains unassociated with LCs are therefore never detected in serum or urine. In the HCDs, the altered structure of the CH1 domain prevents the heavy chain from binding both the LC and HSP78, thereby allowing it to bypass degradation by the proteasome and be secreted into the serum or urine.<sup>4</sup> In addition, recent work suggests that the altered heavy chain, which forms part of the transmembrane B-cell receptor, may facilitate antigen-independent aggregation and

down-stream signaling by the receptor, thereby conferring a growth advantage to neoplastic cells.<sup>5</sup> This characteristic feature gives rise to three different HCDs, depending on the heavy chain class that is produced—each with a unique clinical presentation and characteristic findings on immunologic evaluation and in biopsy specimens of involved tissues. Each HCD appears to represent an unusual variant of a type of lymphoma, and none of them can be defined a true plasma cell neoplasms.<sup>6</sup>

Guido Fanconi, a Swiss pediatrician, described a child with a symptomatology characterized by glycosuria, albuminuria, rickets, and dwarfism.<sup>7</sup> This syndrome bears his name.<sup>8</sup> Environmental agents that cause Fanconi syndrome (FS) include exposure to heavy metals (like cadmium, lead, mercury, platinum, uranium), other substances (lysol, paraquat, toluene, the amino acid lysine taken as a nutritional supplement). Moreover, it may be caused by various drugs, including certain chemotherapeutic drugs (e.g., ifosfamide, streptozotocin), antiretrovirals (e.g., didanosine, zidovudine, tenofovir), and tetracycline. Acquired FS can also occur after renal transplantation and in patients with multiple myeloma, amyloidosis, intoxication with heavy metals or other chemicals, or vitamin D deficiency.<sup>9,10</sup> FS may complicate plasma cell dyscrasias when free LCs (FLCs) undergo homotypic polymerization within the endo-lysosomal system of the proximal tubular epithelium to form intracellular crystals. In this case, it is defined adult acquired FS,<sup>11,12</sup> a rare complication of plasma cell dyscrasias, usually associated with a monoclonal gammopathy of undetermined significance (MGUS). Overt hematologic malignancies may occur, such as multiple myeloma, Waldenström's macroglobulinemia, or other lymphoproliferative disorders.<sup>11,12</sup>

## Heavy-Chains Diseases.

*Epidemiology and clinical features (Table 1).*

$\alpha$ -HCD – It is the most common of the three HCDs, with more than 400 cases described in the literature since its initial description in 1968.<sup>13</sup> It has a striking epidemiology, affecting primarily subjects of Mediterranean, Northern African, and Middle Eastern descent, particularly those of low socio-economic background, suggesting an environmental, possibly infectious, pathogenetic mechanism.<sup>14</sup>

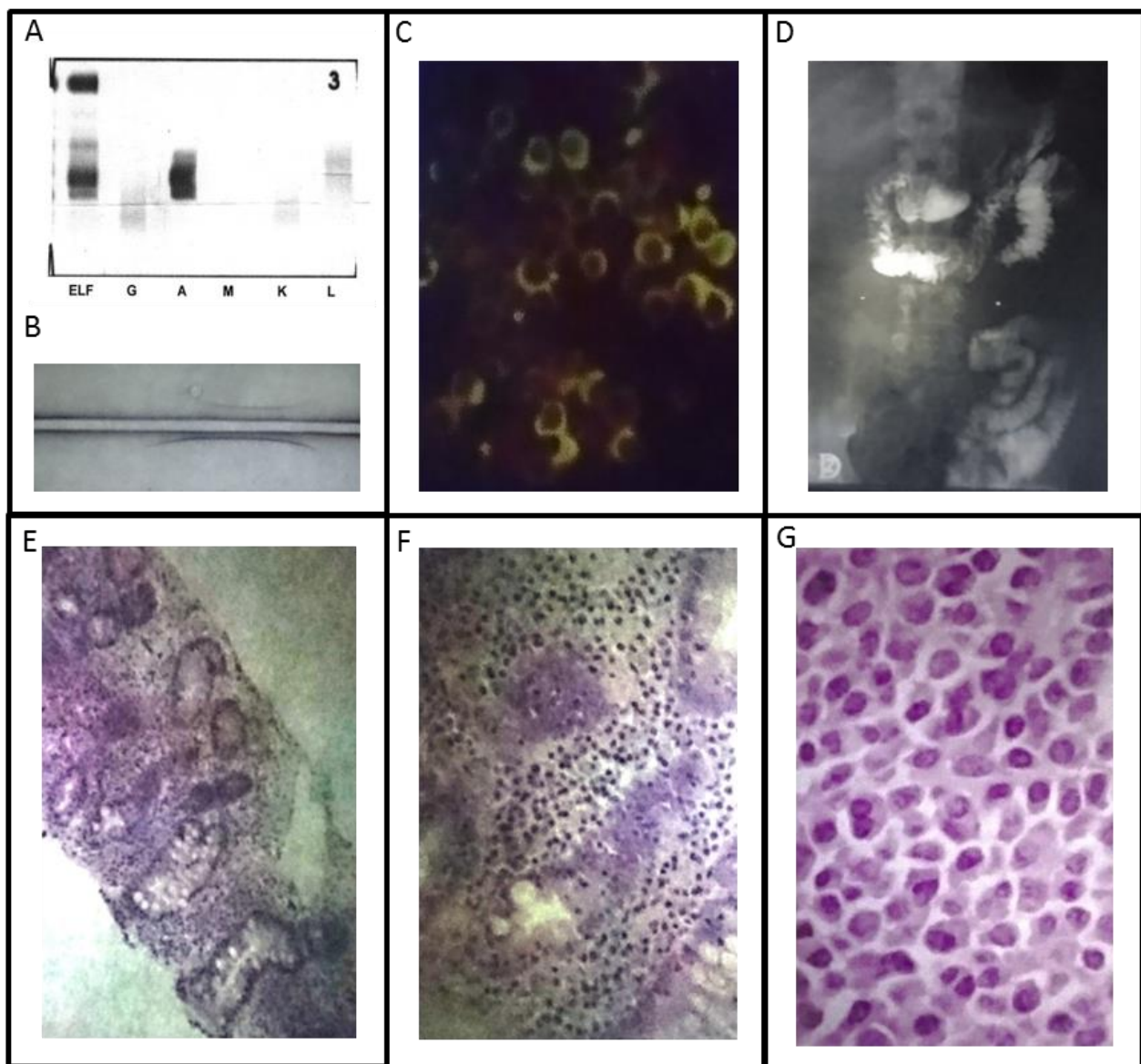
$\alpha$ -HCD is most prevalent during the second and third decades of life, with a slight male predominance, typically affects the gastrointestinal system and rarely the respiratory tract. Lymphoma-like pictures have also been described (**Figure 1**). Malabsorption syndrome with weight loss that can cause growth retardation, amenorrhea, alopecia, diarrhea, and abdominal discomfort are the typical symptoms of gastrointestinal  $\alpha$ -HCD. Nausea and emesis can also be present. In advanced gastrointestinal  $\alpha$ -HCD, ascites and anasarca can be detected at the physical examination. Finger clubbing and tetany can also be seen.<sup>15</sup> Generalized lymphadenopathy and hepato-splenomegaly are hallmarks of the lymphomatous forms that have been recognized as a distinct entity.<sup>16</sup> Patients with respiratory tract involvement show a restrictive pattern on pulmonary function tests. They present dyspnea, mild hypoxemia, and diffuse pulmonary infiltrates and, in some cases, eosinophilia, skin rash, hilar lymphadenopathy, and lymphomatous involvement of the pharyngeal mucosa.<sup>17</sup>

$\gamma$ -HCD – It is also called Franklin's disease, after the physician who first described it in 1964.<sup>18</sup> It is uncommon, with approximately 130 cases reported in the literature, being the age at diagnosis between 51 and 68 years, with a female predominance.<sup>19-21</sup> An autoimmune disease such as rheumatoid arthritis (the most common), Sjögren syndrome, systemic lupus erythematosus, vasculitis, myasthenia gravis and autoimmune cytopenias (particularly idiopathic thrombocytopenic purpura) can be found in about 25% of patients.<sup>22</sup> The manifestations of the associated autoimmune disease often herald the diagnosis of  $\gamma$ -HCD by many years. A lymphoplasmacytic neoplasm is present in 83% to 91% of these patients.

Three different clinical patterns of  $\gamma$ -HCD have been described, based on the presence or absence of an associated lymphoma. In 57% to 66% of patients, a disseminated lymphoma associated with constitutional symptoms (i.e., fever, malaise, and weight loss) is present. Generalized lymphadenopathy, splenomegaly, and hepatomegaly are present in 50% of cases,<sup>14,20</sup> whereas roughly 25% of patients present a lymphomatous bone marrow involvement (localized medullary disease) or a localized extramedullary disease (localized extramedullary disease). This last form commonly involves the skin, less

**Table 1.** Clinicopathologic features of heavy chain disease.

	Main site of involvement	Underlying disorders	Associated diseases	References
$\alpha$ -HCD	Gastrointestinal system; Respiratory system	Immunoproliferative small intestinal disease (IPSID) with features of MALT lymphoma	Bacteria and parasites infection of bowel	14-17
$\gamma$ -HCD	Bone marrow, spleen, lymph nodes, extra-nodal sites	Lymphoplasmacytic neoplasm: - disseminated lymphoma; - localized medullary disease; - localized extramedullary disease. Autoimmune disease	Rheumatoid arthritis and less frequently other autoimmune diseases	20-22,33-35
$\mu$ -HCD	Bone marrow	Lymphoid neoplasm with features of chronic lymphocytic leukemia/small lymphocytic lymphoma	Hepato-splenomegaly, recurrent pulmonary infections, portal hypertension, systemic lupus erythematosus, diffuse large B-cell lymphoma of the breast, myelodysplastic syndrome, systemic amyloidosis	1,25,26-29



**Figure 1.** Clinicopathologic features in a case of IPSID with  $\alpha$ -HCD. **A)** Immunofixation and **B)** immunoelectrophoresis positivity for the anti-IgA antiserum; **C)** plasma cells and marginal zone cells express monoclonal cytoplasmic  $\alpha$ -chain at immunofluorescence; **D)** Radiologic studies of the gastrointestinal apparatus showing diameter alterations (dilations and strictures); **E), F)** and **G)** histological features of intestinal infiltration by  $\alpha$ -HCD cells (10X, 20X and 100X respectively).

frequently the thyroid or parotid gland, the oropharyngeal cavity, and the gastrointestinal tract.<sup>20,22</sup> Finally, 10-17% of patients have a pre-existing autoimmune disease with a clinical presentation characterized by rheumatoid nodules, rashes, synovitis, and joint deformities.

**$\mu$ -HCD.** – It is the rarest of the HCDs, with only 30 to 40 cases reported in the literature. The first two patients were described in 1970 by Forte et al.<sup>23</sup> and Ballard et al.<sup>24</sup> The disease occurs predominantly in Caucasian males, with a median age of 58 years at diagnosis.<sup>14</sup> Most patients with  $\mu$ -HCD have a lymphoid neoplasm resembling chronic lymphocytic leukemia/small lymphocytic lymphoma.<sup>1,25</sup>

Palpable, superficial lymphadenopathy can be identified in 40% of the patients. Splenomegaly is frequent, and hepatomegaly can be found in about 25%.<sup>14</sup> Rare associations of  $\mu$ -HCD with recurrent pulmonary infections, portal hypertension, and pancytopenia, systemic lupus erythematosus, diffuse large B-cell lymphoma of the breast as well as myelodysplastic syndrome, carpal tunnel syndrome, and systemic amyloidosis have been reported.<sup>26-29</sup>

**Diagnostic Approach.** The diagnosis of HCDs remains challenging due to their rarity, their variable clinical presentation, and the skill required in interpreting immunologic laboratory tests and tissue biopsies from affected patients. A close collaboration between clinicians and pathologists is usually needed. Two-dimensional immunoelectrophoresis has been shown to be a useful diagnostic tool for all three types of HCD.<sup>30</sup>

**$\alpha$ -HCD.** - Common laboratory abnormalities include mild-to-moderate hypochromic anemia, deficiency of vitamins and minerals, high levels of alkaline phosphatase (the gastrointestinal isoform of the enzyme), electrolytic disorders (i.e., hypoalbuminemia, hypocalcemia, hypokalemia, and hypomagnesemia).<sup>15</sup> Serum protein electrophoresis may appear normal or show hypogammaglobulinemia, but sometimes a broad monoclonal band migrating to the  $\alpha_2$  or  $\beta$  region of the electrophoretic pattern can be seen. Positivity for the anti-IgA antiserum by immunofixation is mandatory to confirm the diagnosis (**Figure 1** panel **A, B**).<sup>31</sup> The abnormal  $\alpha$ -heavy chains can be detected in jejunal or gastric fluids as well as in urine in only small

amounts, but Bence Jones proteinuria has never been detected.<sup>31</sup>

Radiologic studies of the gastrointestinal apparatus can show diameter alterations (dilations and strictures) (**Figure 1** panel **D**), hypertrophic or pseudo-polypoid mucosa, or coarse mucosal folds.

Since  $\alpha$ -HCD typically affects the proximal small bowel at the level of the duodenum or jejunum, endoscopy is mandatory and can reveal five different patterns: *i*) infiltrative, *ii*) nodular, *iii*) ulcerations, *iv*) mosaic, *v*) isolated mucosal fold thickening. The first two patterns are most sensitive and characteristic for the diagnosis of  $\alpha$ -HCD.<sup>32</sup>

The histological features of  $\alpha$ -HCD are those of an extranodal marginal zone lymphoma of mucosa-associated lymphoid tissue (MALT lymphoma) (**Figure 1** panel **E, F, G**), also named immunoproliferative small intestinal disease (IPSID). Bacterial or parasites infection (i.e., *Campylobacter jejuni* or *Helicobacter pylori*) can be associated.<sup>33-35</sup> A lymphoplasmacytic infiltrate rich in plasma cells can be detected in the lamina propria of the bowel, and lymphoepithelial lesions may also be present. The infiltrate can cause villous atrophy and is admixed with small lymphocytes, resembling marginal zone B cells.<sup>33,36-38</sup> All the  $\alpha$ -heavy chain cells (plasma cells and marginal zone cells) typically express monoclonal cytoplasmic  $\alpha$ -chain without light chains (**Figure 1** panel **C**). The immunophenotype of  $\alpha$ -heavy chain cells is shown in **Table 2**. Finally, the presence of intestinal bacteria and parasites should be looked for on biopsy specimens.

**$\gamma$ -HCD.** - Laboratory evidence of autoimmune diseases or bone marrow infiltration can be detected during diagnostic procedures in patients with  $\gamma$ -HCD. These comprise cytopenias, in particular, normochromic normocytic anemia, Coombs-positive autoimmune hemolytic anemia, and thrombocytopenia. In some cases, monoclonal plasmacytoid lymphocytes or plasma cells are present in the circulation, as well as features of chronic lymphocytic leukemia or plasma cell leukemia.<sup>14</sup> Serum protein electrophoresis may appear normal or show a monoclonal band migrating to the  $\beta$ -region of the electrophoretic pattern, where it is often concealed by other proteins. Rarely, biclonal gammopathy with an additional intact monoclonal Ig may be present.<sup>20</sup> Positivity for the anti-IgG antiserum, without

associated light chains, by immunofixation is mandatory to confirm the diagnosis.

Due to their low molecular weight and existence as dimers, the abnormal  $\gamma$ -heavy chains often can be detected in the urine.<sup>2</sup> Small amounts of FLCs may be excreted in urine as Bence Jones protein.<sup>39</sup> Other laboratory findings include high serum levels of IgG, with normal serum FLCs.

The pathologic heterogeneity of  $\gamma$ -HCD makes the histological diagnosis rather difficult. Histological findings of  $\gamma$ -HCD are typically associated with a lymphomatous infiltration of affected tissues such as bone marrow, spleen, lymph nodes, as well as extra-nodal sites involved in MALT lymphomas, such as skin, thyroid, salivary glands, gastrointestinal tract, and conjunctiva.<sup>21,22</sup> The infiltrate is formed by a mixed population of lymphocytes, plasmacytoid lymphocytes, and plasma cells, similarly to a lymphoplasmacytic lymphoma or, in some cases, it is more polymorphous showing immunoblasts, eosinophils, and histiocytes in a variable number. Atypical Reed-Sternberg-like cells have been described, thus inducing Hodgkin lymphoma or certain types of peripheral T-cell lymphoma to be considered in a morphologic differential diagnosis.<sup>22</sup> Less frequently,  $\gamma$ -HCD can be similar to B-cell neoplasms, such as MALT lymphoma, splenic marginal zone lymphoma, or other splenic small B-cell lymphomas.<sup>21</sup> The association of  $\gamma$ -HCD with T-cell large granular lymphocytic leukemia and extranodal marginal zone lymphoma have also been reported.<sup>40,41</sup>

The immunophenotype of  $\gamma$ -heavy chain cells is shown in **Table 2**.

$\mu$ -HCD. – Hypoproliferative anemia related to bone marrow infiltration by neoplastic cells is the most common laboratory abnormality of  $\mu$ -HCD; thrombocytopenia and lymphocytosis are less common.<sup>27,28</sup> Serum protein electrophoresis is generally normal or shows a rather broad monoclonal band. In a few cases, biclonal gammopathy with an additional intact monoclonal Ig may be present.<sup>1</sup> Immunofixation that is positive with anti- $\mu$  but not with anti-kappa or anti-lambda LCs confirms the diagnosis.<sup>42</sup> Bence Jones proteinuria is frequently detected because the neoplastic cells also produce monoclonal LCs, usually of kappa type, that fail to assemble with the truncated heavy chain;<sup>1,24,42</sup> however, Bence Jones proteinuria rarely causes renal complications.<sup>43</sup>

**Table 2:** Immunophenotypic characteristics of HCD cells.

	Heavy chain	Cell phenotypes	References
$\alpha$ -HCD	IgA	pan-B-cell antigens+ CD138+ CD5- CD10- CD20-	22,32
$\gamma$ -HCD	IgG	CD19+ CD20+ Mum1/IRF4+ CD38+ CD138+ CD5- CD10-	4,21
$\mu$ -HCD	IgM	CD19+ CD20+ CD38+ k light chain+ (rare) CD5+ (rare)	1,28,42

Bone marrow smears and touch preparations show characteristic plasma cells with prominent cytoplasmic vacuoles admixed with small, round lymphocytes.<sup>1,24,44,45</sup> The immunophenotype of  $\mu$ -heavy chain cells is shown in **Table 2**.

*Treatment and Prognosis.* No standardized therapies are available for the HCDs, because of their rarity and their clinicopathologic features characterized by association with various conditions such as infectious, autoimmune and lymphoproliferative diseases.

$\alpha$ -HCD. - Since it has a higher incidence in subjects of lower socio-economic status, sanitation improvement would be expected to reduce its occurrence. If untreated,  $\alpha$ -HCD may initially progress locally, and then spread systemically. Small bowel obstruction, perforation, and intussusception that can be fatal are the dreadful local complications of enlargement of the lymphomatous tissue. Other potential causes of death are severe malnutrition and subsequent cachexia, as well as infectious complications.<sup>46</sup>

If a bacterial or parasitic gastro-intestinal infection is documented, it should be eradicated with appropriate antimicrobial therapy. An empirically administered antibiotic treatment is often recommended even in the absence of a demonstrated infection. Metronidazole, ampicillin, or tetracycline are the antibiotics of choice for this empiric therapy. Antimicrobial treatment should be administered for a 6-months course, although an early regression or a rapid improvement of symptoms is typically observed in antibiotic-

sensitive patients. A shorter duration has been shown to cause a relapse of the disease.

Although 33-71% of patients with early-stage show clinical, laboratory, and histological remission in response to antimicrobial treatment, disease recurrences are frequent.<sup>47</sup> Refractory disease is treated with either total abdominal radiation or, more commonly, with doxorubicin-containing combination chemotherapy. Regimens such as CHOP (cyclophosphamide, doxorubicin, vincristine, and prednisone), CHVP (cyclophosphamide, doxorubicin, teniposide, and prednisone), or ABV (doxorubicin, bleomycin, and vinblastine) have been shown to induce better results than doxorubicin-free regimens such as COPP (cyclophosphamide, vincristine, procarbazine, and prednisolone).<sup>48-50</sup> The complete remission rate after treatment with multi-drug chemotherapy is 64%, and 5-year overall survival is 67%.<sup>51</sup>

Surgical debulking of the tumor mass can be pursued, followed by systemic chemotherapy, but it should be limited to the management of complications.<sup>52</sup> For patients with a refractory or relapsing disease, high-dose therapy with autologous hematopoietic stem cell transplantation should be considered.

**$\gamma$ -HCD.** - Treatment of  $\gamma$ -HCD is typically tailored to the symptomatology of the patient and to the presence of an accompanying autoimmune disease or overt lymphoma. Chemotherapy is recommended in patients with lymphomatous dissemination or with a localized medullary disease. Chlorambucil, or melphalan and prednisone, or bortezomib and prednisone, and rituximab in CD20-positive disease are the treatment of choice for plasma cell-predominant disease. CHOP regimen (with rituximab in CD20-positive cases) shows the best results in aggressive/refractory patients. Inoue et al.<sup>53</sup> reported that the combination of fludarabine and rituximab was effective in patients with  $\gamma$ -HCD associated with pancytopenia.

While surgical resection or radiation therapy have been successfully employed in patients with localized extra-nodal disease,<sup>22</sup> a 'watch and wait' strategy can be adopted in asymptomatic patients without lymphoma. When co-existing autoimmune disorders are diagnosed, they should be treated with immunosuppressive treatments according to usual guidelines. Adequate prophylaxis and surveillance for infectious complications are

critical points. Prognosis is highly variable because of the heterogeneity of  $\gamma$ -HCD and the lack of a standardized treatment.

Occasional spontaneous remissions have been reported in patients with no overt lymphoma, who are nonetheless expected to undergo a prolonged survival without treatment.<sup>22</sup> A sustained, complete clinical and immunologic remission is usually achieved in patients with treated, localized lymphoma. The natural history of  $\gamma$ -HCD associated with systemic lymphoma may be either aggressive and rapidly progressive, and hence associated with poor prognosis, or exhibit an indolent course. In the Mayo Clinic series, median survival was 7.4 years (range, one month to more than two decades).<sup>20</sup>

**$\mu$ -HCD.** - Only a few data have been reported about the treatment and prognosis of this disease because of its rarity. A 'watch and wait' approach is recommended in patients with detectable monoclonal  $\mu$  heavy chains who are otherwise asymptomatic.<sup>54</sup> If and when an underlying malignancy develops, useful treatment regimens are CHOP, CVP (cyclophosphamide, vincristine, and prednisone), single-agent fludarabine or cyclophosphamide.<sup>14,45</sup> Reported median overall survival is approximately two years, ranging from less than a month to over a decade. However, these data are likely underestimated, since the presence of monoclonal  $\mu$  heavy chains is frequently missed on serum protein electrophoresis, especially in the absence of an associated overt lymphoma. A spontaneous remission of  $\mu$ -HCD can rarely be observed.<sup>14</sup>

### **Myeloma-Associated Fanconi Syndrome (MAFS).**

**Pathophysiology.** The precise pathophysiology of MAFS is still unknown. The biological and clinical features result from the impaired function of the proximal renal tubule, consequent to reabsorption of some filtered substances.<sup>55,56</sup> In particular, FLCs, generally of kappa isotype, secreted by plasma cells are a major cause of MAFS or other plasma cell dyscrasias. In virtually all cases, the diagnosis of FS precedes that of the underlying hematological disorder, generally a 'smoldering' multiple myeloma.<sup>11,12</sup>

FLCs slowly accumulate in the epithelial cells of the proximal tubule, forming crystals that can be demonstrated in all cases.<sup>11,57,58</sup> Accumulation and crystallization take place in the lysosomes of

tubular cells and endoplasmic reticulum of plasma cells. These LCs have the highest homology with a single germline variable segment sequence: LCO2/O12 and non-polar amino acid residues exposed in the CDR1 region.<sup>56-58</sup> This peculiar sequence is responsible for the crystallization because of the resistance of the LC variable domain to proteolysis by several enzymes such as cathepsin B<sup>54,55</sup> and of the subsequent damage of the proximal tubule. The functional impairment of the proximal kidney tubule can cause aminoaciduria, glycosuria with normal glycemia, metabolic acidosis and increased clearances of uric acid and phosphate. Phosphate loss is responsible for osteomalacia, with bone pain and pseudo-fractures.<sup>59,60</sup> Intracellular crystallization seems associated with the slowly proliferative character of the tumor, in that the intracellular accumulation of crystals impairs the proliferation of plasma cells, and this may be a criterion for not treating the proliferative disease.<sup>61-62</sup>

In contrast, when the LC variable domain derives from another germline variable segment such as LCO8/O18, MAFS occurs without evidence of intracellular crystallization, even when searched for by electron microscopy.<sup>63,64</sup> In this case, defects of tubular reabsorption and urine acidification are usually a consequence of the direct toxicity of FLCs on epithelial cells of the proximal tubule, in the absence of crystalline deposits.<sup>65</sup> Myeloma FLCs can interfere with the uptake of alanine, phosphate, and glucose.<sup>66,67</sup> There has also been one report of LC-FS and nephrogenic diabetes insipidus, suggesting that resistance to antidiuretic hormone can also occur.<sup>68</sup> Interestingly, this patient had distal (type D), not proximal, renal tubular acidosis.

*Clinical features and diagnostic approach.* Clinical manifestations of MAFS include defects in sodium-coupled co-transport processes producing type II renal tubular acidosis, aminoaciduria, phosphaturia, and glycosuria. The associated multiple myeloma is often low-grade.<sup>11</sup> The offending monoclonal FLCs are usually of the kappa type and possess uncommon non-polar or hydrophobic residues in the complementarity-determining region-1 (CDR1).<sup>61</sup> This unique proximal tubular lesion may represent a subset of gammopathy-associated crystal-storing histiocytosis, in which crystal-forming monoclonal Igs, composed of heavy chains and typically

kappa-FLC, accumulate in lysosomes of histiocytes in soft tissues, kidney, bone marrow, spleen, liver, stomach, and other organs.<sup>69-70</sup> Involvement of the proximal tubule occurs specifically when the monoclonal FLCs are overproduced, because intact Igs are not filtered through the glomerulus.

The typical histological finding is intra-lysosomal crystalline deposits of FLCs within epithelial cells of the proximal tubule. There may be extra-renal crystal accumulation. FLCs of the VkI subgroup are most frequently found,<sup>61,62</sup> although cases associated with lambda-FLCs have also been reported.<sup>71</sup>

The diagnosis of FS can be made when a patient with a monoclonal plasma cell disorder presents with hypophosphatemia, hypouricemia, aminoaciduria, phosphaturia, and glycosuria. Bence Jones proteinuria is usually present and is almost always of the kappa type. Crystal-storing histiocytosis, an intra-lysosomal accumulation of monoclonal LCs that aggregate in crystals, is observed in association with both plasma cell and lymphoid disorders.<sup>72,73</sup> Although the type of LCs involved is almost exclusively kappa, there is no consistent association with a particular heavy chain. Crystals can form either in histiocytes in soft tissues or parenchymal cells in bone marrow, lymph nodes, spleen, liver, stomach, adrenal glands, proximal renal tubules, and thyroid follicles. The initial clinical presentation depends on the site of crystal formation and is, therefore, variable. Some patients present with soft tissue masses in which predominantly histiocytes, but also fibroblasts, contain crystals. The crystal formation in proximal renal tubules is the fundamental diagnostic criterion of MAFS.

The main laboratory abnormalities include aminoaciduria, renal glycosuria, hypophosphatemia, hyperchloremic metabolic acidosis, hypokalemia, proteinuria of tubular origin, and hypouricemia. The primary manifestations include osteomalacia, polyuria, chronic acidosis, and episodes of dehydration. FS frequently evolves into end-stage renal failure.

*Treatment and prognosis.* The prognosis in terms of survival is good in the absence of an overt malignancy. Treatment includes symptomatic measures to prevent osteomalacia by supplementation with phosphorus, calcium, and vitamin D. Chemotherapy may benefit patients

with rapidly progressive renal failure or symptomatic malignancy.

Very few series of LC-associated FS have been published, and the efficacy of the so-called novel anti-myeloma agents, such as proteasome inhibitors and immunomodulatory drugs (IMiDs), has not been evaluated. In most cases, FS appears to progress toward end-stage renal disease slowly and rarely results in symptomatic myeloma.<sup>74</sup> Accordingly, therapeutic decisions should take into account treatment side effects, particularly the potential risk of secondary myelodysplastic syndrome from alkylating agents.<sup>75</sup>

All patients with an associated overt lymphoid disorder should receive appropriate chemotherapy, and treatment choices should be adapted to the degree of renal failure. In patients with stages 1 to 3 chronic kidney disease, bortezomib-based chemotherapy should be considered because of high rates of both anti-myeloma response and recovery of renal function. In addition, cyclophosphamide- or IMiDs-based regimens are good options to treat bortezomib-refractory myeloma. Bendamustine may also be used. High-dose melphalan/autologous stem cell

transplantation (HDM/ASCT) may be performed in selected non-responding patients, although the benefit of this strategy remains to be proven. In the relapsed/refractory setting, additional treatment options such as carfilzomib, pomalidomide and monoclonal antibodies are now available. However, limited data have been reported as regards their effects on patients with renal impairment.<sup>76</sup>

In patients with stages 4 to 5 chronic kidney disease who are eligible for renal allograft, chemotherapy, including HDM/ASCT, should be considered either before or after transplantation. In patients who are not candidates for renal transplantation, administration of chemotherapy does not result in particular benefits.<sup>76</sup>

**Acknowledgments.** This study was supported by the Italian Association for Cancer Research (AIRC, Milan), Investigator grant 2013 (no. 14095), the five per thousand Molecular Clinical Oncology Special Program (grant no. 9965; to A. Vacca), and grants from MIUR PRIN 2009WCNS5C\_004 (to R. Ria) and 2010NECHBX (to A. Vacca).

## References:

1. Wahner-Roedler DL, Kyle RA. Mu-heavy chain disease: presentation as a benign monoclonal gammopathy. *Am J Hematol.* 1992;40:56-60. <https://doi.org/10.1002/ajh.2830400112>
2. Feraud JP, Brouet JC. Heavy-chain diseases. *Hematol Oncol Clin North Am.* 1999;13:1281-94. [https://doi.org/10.1016/S0889-8588\(05\)70127-1](https://doi.org/10.1016/S0889-8588(05)70127-1)
3. Goossens T, Klein U, Kuppers R. Frequent occurrence of deletions and duplications during somatic hypermutation: implications for oncogene translocations and heavy chain disease. *Proc Natl Acad Sci U S A.* 1998;95:2463-8. <https://doi.org/10.1073/pnas.95.5.2463>
4. Munshi NC, Digumarthy S, Rahemtullah A. Case records of the Massachusetts General Hospital. Case 13-2008. A 46-year-old man with rheumatoid arthritis and lymphadenopathy. *N Engl J Med.* 2008;358:1838-48. <https://doi.org/10.1056/NEJMcp0800959>
5. Corcos D, Osborn MJ, Matheson LS. B-cell receptors and heavy chain diseases: guilty by association? *Blood.* 2011;117:6991-8. <https://doi.org/10.1182/blood-2011-02-336164>
6. Harris NL, Isaacson PG, Grogan TM, Jaffe ES. Heavy chain diseases. In: Swerdlow SH, Campo E, Harris NL, et al., editors. *WHO classification of tumours of the haematopoietic and lymphoid tissues.* Lyon: IARC; 2008;196-9.
7. Fanconi G. Der fruhinfantile nephrotisch-glykosurische Zwergwuchs mit hypophosphatamischer Rachitis. *Jahrb Kinderheilkunde (Berlin).* 1936;147:299-338.
8. Lobitz S, Velleuer E. Guido Fanconi (1892-1979): a jack of all trades. *Nat Rev Cancer.* 2006;6:893-898. <https://doi.org/10.1038/nrc2009>
9. Hall AM, Bass P, Unwin RJ. Drug-induced renal Fanconi syndrome. *QJM.* 2014;107:261-9. <https://doi.org/10.1093/qjmed/hct258>
10. Foreman JW. Fanconi syndrome and other proximal tubule disorders. In: *Comprehensive Clinical Nephrology, 5th Edition.* Richard JJ, Feehally J, Floege J eds. 2014; pp 590-600.
11. Maldonado JE, Velosa JA, Kyle RA, Wagoner RD, Holley KE, Salassa RM. Fanconi syndrome in adults. A manifestation of a latent form of myeloma. *Am J Med.* 1975;58:354-364. [https://doi.org/10.1016/0002-9343\(75\)90601-4](https://doi.org/10.1016/0002-9343(75)90601-4)
12. Schilling F, Hopfner C, Montagnac R, Milcent T. IgG kappa myeloma with Fanconi's syndrome and crystalline inclusions. *Immunohistochemical and ultrastructural study.* *Presse Méd.* 1993;22:675-679.
13. Seligmann M, Danon F, Hurez D, Mihaesco E, Preud'homme JL. Alpha-chain disease: a new immunoglobulin abnormality. *Science.* 1968;162:1396-7. <https://doi.org/10.1126/science.162.3860.1396>
14. Wahner-Roedler DL, Kyle RA. Heavy chain diseases. *Best Pract Res Clin Haematol.* 2005;18:729-46. <https://doi.org/10.1016/j.beha.2005.01.029>
15. Doe WF, Henry K, Hobbs JR, Jones FA, Dent CE, Booth CC. Five cases of alpha chain disease. *Gut.* 1972;13:947-57. <https://doi.org/10.1136/gut.13.12.947>
16. Takahashi K, Naito M, Matsuoka Y, Takatsuki K. A new form of the alpha-chain disease with generalized lymph node involvement. *Pathol Res Pract.* 1988;183:717-23. [https://doi.org/10.1016/S0344-0338\(88\)80057-8](https://doi.org/10.1016/S0344-0338(88)80057-8)
17. Stoop JW, Ballieux RE, Hijmans W, Zegers BJ. Alpha-chain disease with involvement of the respiratory tract in a Dutch child. *Clin Exp Immunol.* 1971;9:625-35.
18. Franklin EC, Lowenstein J, Bigelow B, Meltzer M. Heavy chain disease—a new disorder of serum gamma-globulins: report of the first case. *Am J Med.* 1964;37:332-50. [https://doi.org/10.1016/0002-9343\(64\)90191-3](https://doi.org/10.1016/0002-9343(64)90191-3)
19. Dammacco F, Rigoli E, Ferrarese M, Bonomo L. Gamma heavy chain disease in a young girl. *Haematologica.* 1976;61:278-290.
20. Wahner-Roedler DL, Witzig TE, Loehrer LL, Kyle RA. Gamma-heavy chain disease: review of 23 cases. *Medicine (Baltimore).* 2003;82:236-50. <https://doi.org/10.1097/01.md.0000085058.63483.7f>
21. Bieliauskas S, Tubbs RR, Bacon CM, Eshoa C, Foucar K, Gibson SE, Kroft SH, Sohani AR, Swerdlow SH, Cook JR. Gamma heavy-chain disease: defining the spectrum of associated lymphoproliferative disorders through analysis of 13 cases. *Am J Surg Pathol.* 2012;36:534-43. <https://doi.org/10.1097/PAS.0b013e318240590a>
22. Feraud JP, Brouet JC, Danon F, Seligmann M. Gamma heavy chain disease: heterogeneity of the clinicopathologic features. Report of 16 cases and review of the literature. *Medicine (Baltimore).* 1989;68:321-35. <https://doi.org/10.1097/00005792-198911000-00001>
23. Forte FA, Prelli F, Yount WJ, Jerry LM, Kochwa S, Franklin EC,



- Kunkel HG. Heavy chain disease of the gamma (gamma M) type: report of the first case. *Blood*. 1970;36:137-44.
24. Ballard HS, Hamilton LM, Marcus AJ, Illes CH. A new variant of heavy-chain disease (mu-chain disease). *N Engl J Med*. 1970;282:1060-2. <https://doi.org/10.1056/NEJM197005072821902>
  25. Dammacco F, Bonomo L, Franklin EC. A new case of mu heavy chain disease: clinical and immunochemical studies. *Blood*. 1974;43:713-719.
  26. Witzens M, Egerer G, Stahl D, Werle E, Goldschmidt H, Haas R. A case of mu heavy-chain disease associated with hyperglobulinemia, anemia, and a positive Coombs test. *Ann Hematol*. 1998;77:231-4. <https://doi.org/10.1007/s002770050448>
  27. Iwasaki T, Hamano T, Kobayashi K, Kakishita E. A case of mu-heavy chain disease: combined features of mu-chain disease and macroglobulinemia. *Int J Hematol*. 1997;66:359-65. [https://doi.org/10.1016/S0925-5710\(97\)00039-X](https://doi.org/10.1016/S0925-5710(97)00039-X)
  28. Maeda A, Mori M, Torii S, Nagai Y, Togami K, Fujita H, Kurata M, Matsushita A, Nagai K, Imai Y, Takahashi T. Multiple extranodal tumors in mu-heavy chain disease. *Int J Hematol*. 2006;84:286-7. <https://doi.org/10.1532/IJH97.06124>
  29. Kinoshita K, Yamagata T, Nozaki Y, Sugiyama M, Ikoma S, Funouchi M, Kanamaru A. Mu-heavy chain disease associated with systemic amyloidosis. *Hematology*. 2004;9:135-7. <https://doi.org/10.1080/10245330410001671561>
  30. Dammacco F, Antonaci S, Miglietta A. Two-dimensional immunoelectrophoresis as a diagnostic tool for heavy chain disease. *Boll Ist Sieroter Milan*. 1975;54:460-465.
  31. Seligmann M. Alpha chain disease: immunoglobulin abnormalities, pathogenesis and current concepts. *Br J Cancer Suppl*. 1975;2:356-61. <https://doi.org/10.1136/jcp.s1-6.1.72>
  32. Al-Saleem T, Al-Mondhiry H. Immunoproliferative small intestinal disease (IPSID): a model for mature B-cell neoplasms. *Blood*. 2005;105:2274-80. <https://doi.org/10.1182/blood-2004-07-2755>
  33. Lecuit M, Abachin E, Martin A, Poyart C, Pochart P, Suarez F, Bengoufa D, Feuillard J, Lavergne A, Gordon JJ, Berche P, Guillevin L, Lortholary O. Immunoproliferative small intestinal disease associated with *Campylobacter jejuni*. *N Engl J Med*. 2004;350:239-48. <https://doi.org/10.1056/NEJMoa031887>
  34. Peterson MC. Immunoproliferative small intestinal disease associated with *Campylobacter jejuni*. *Engl J Med*. 2004;350:1685-6. <https://doi.org/10.1056/NEJM200404153501619>
  35. Isaacson PG. Extranodal marginal zone lymphoma: MALT lymphoma. In: Jaffe ES, Harris NL, Vardiman JW, et al, editors. *Hematopathology*. St. Louis: Elsevier; 2011. p. 291-305. <https://doi.org/10.1016/B978-0-7216-0040-6.00018-6>
  36. Halphen M, Najjar T, Jaafoura H, Cammoun M, Tufrafi G. Diagnostic value of upper intestinal fiber endoscopy in primary small intestinal lymphoma. A prospective study by the Tunisian-French Intestinal Lymphoma Group. *Cancer*. 1986;58:2140-5. [https://doi.org/10.1002/1097-0142\(19861101\)58:9<2140::AID-CNCR2820580930>3.0.CO;2-P](https://doi.org/10.1002/1097-0142(19861101)58:9<2140::AID-CNCR2820580930>3.0.CO;2-P)
  37. Isaacson PG, Dogan A, Price SK, Spencer J. Immunoproliferative small-intestinal disease. An immunohistochemical study. *Am J Surg Pathol*. 1989;13:1023-33. <https://doi.org/10.1097/0000478-198912000-00004>
  38. Parsonnet J, Isaacson PG. Bacterial infection and MALT lymphoma. *N Engl J Med*. 2004;350:213-5. <https://doi.org/10.1056/NEJMp038200>
  39. Presti BC, Sciotto CG, Marsh SG. Lymphocytic lymphoma with associated gamma heavy chain and IgM-lambda paraproteins. An unusual biclonal gammopathy. *Am J Clin Pathol*. 1990;93:137-41. <https://doi.org/10.1093/ajcp/93.1.137>
  40. Zhang L, Sotomayor EM, Papenhausen PR, Shao H, Moscinski LC, Sandin RL, Caceres G, Valenica H, Malafa M, List AF, Sokol L. Unusual concurrence of T-cell large granular lymphocytic leukemia with Franklin disease (gamma heavy chain disease) manifested with massive splenomegaly. *Leuk Lymphoma*. 2013;54:205-8. <https://doi.org/10.3109/10428194.2012.697561>
  41. Wahbi A, Neel A, Perrin F, Gravelleau J, Mahe B, Dejoie T, Hamidou M. Gamma heavy chain disease associated with large granular lymphocytic leukemia: A report of two cases and review of the literature. *Hematology*. 2016;21:92-4.
  42. Maisnar V, Tichy M, Stulik J, Urban P, Adam Z, Kadlcikova E, Vavrova J, Palicka V, Jebavy L, Kodet R, Buchler T, Hajek R. Capillary immunotyping electrophoresis and high-resolution two-dimensional electrophoresis for the detection of mu-heavy chain disease. *Clin Chim Acta*. 2008;389:171-3. <https://doi.org/10.1016/j.cca.2007.10.035>
  43. Preud'homme JL, Bauwens M, Dumont G, Goujon JM, Dreyfus B, Touchard G. Cast nephropathy in mu heavy chain disease. *Clin Nephrol*. 1997;48:118-21.
  44. Courtois L, Sujobert P. Morphologic features of  $\mu$ -heavy-chain disease. *Blood*. 2017;130:558. <https://doi.org/10.1182/blood-2017-04-781344>
  45. Yanai M, Maeda A, Watanabe N, Sugimoto N, Matsushita A, Nagai K, Oida T, Takahashi T. Successful treatment of mu-heavy chain disease with fludarabine monophosphate: a case report. *Int J Hematol*. 2004;79:174-7. <https://doi.org/10.1532/IJH97.03053>
  46. Bonomo L, Dammacco F, Marano R, Bonomo GM. Abdominal lymphoma and alpha chain disease. Report of three cases. *Am J Med*. 1972;52:73-86. [https://doi.org/10.1016/0002-9343\(72\)90009-5](https://doi.org/10.1016/0002-9343(72)90009-5)
  47. Alpha-chain disease and related small-intestinal lymphoma: a memorandum. *Bull World Health Organ*. 1976;54:615-24.
  48. Fine KD, Stone MJ. Alpha-heavy chain disease, Mediterranean lymphoma, and immunoproliferative small intestinal disease: a review of clinicopathological features, pathogenesis, and differential diagnosis. *Am J Gastroenterol*. 1999;94:1139-52. <https://doi.org/10.1111/j.1572-0241.1999.01057.x>
  49. Ben-Ayed F, Halphen M, Najjar T, Boussene H, Jaafoura H, Bouguerra A, Ben Salah N, Mourali N, Ayed K, Ben Khalifa H, Garoui H, Gargouri M, Tufrafi G. Treatment of alpha chain disease. Results of a prospective study in 21 Tunisian patients by the Tunisian-French intestinal Lymphoma Study Group. *Cancer*. 1989;63:1251-6. [https://doi.org/10.1002/1097-0142\(19890401\)63:7<1251::AID-CNCR2820630704>3.0.CO;2-H](https://doi.org/10.1002/1097-0142(19890401)63:7<1251::AID-CNCR2820630704>3.0.CO;2-H)
  50. Salem PA, Estephan FF. Immunoproliferative small intestinal disease: current concepts. *Cancer J*. 2005;11:374-82. <https://doi.org/10.1097/00130404-200509000-00003>
  51. Akbulut H, Soykan I, Yakaryilmaz F, Icii F, Aksoy F, Haznedaroglu S, Yildirim S. Five-year results of the treatment of 23 patients with immunoproliferative small intestinal disease: a Turkish experience. *Cancer*. 1997;80:8-14. [https://doi.org/10.1002/\(SICI\)1097-0142\(19970701\)80:1<8::AID-CNCR2>3.0.CO;2-T](https://doi.org/10.1002/(SICI)1097-0142(19970701)80:1<8::AID-CNCR2>3.0.CO;2-T)
  52. Martin IG, Aldoori MI. Immunoproliferative small intestinal disease: Mediterranean lymphoma and alpha heavy chain disease. *Br J Surg*. 1994;81:20-4. <https://doi.org/10.1002/bjs.1800810107>
  53. Inoue D, Matsushita A, Kiuchi M, Takiuchi Y, Nagano S, Arima H, Mori M, Tabata S, Yamashiro A, Maruoka H, Oita T, Imai Y, Takahashi T. Successful treatment of gamma-heavy-chain disease with rituximab and fludarabine. *Acta Haematol*. 2012;128:139-43. <https://doi.org/10.1159/000339097>
  54. Witzig TE, Wahner-Roedler DL. Heavy chain disease. *Curr Treat Options Oncol*. 2002;3:247-54. <https://doi.org/10.1007/s11864-002-0014-3>
  55. Lee DB, Drinkard JP, Rosen VJ, Gonick HC. The adult Fanconi syndrome: observations on etiology, morphology, renal function and mineral metabolism in three patients. *Medicine (Baltimore)*. 1972;51:107-138. <https://doi.org/10.1097/00005792-197203000-00003>
  56. Aucouturier P, Bauwens M, Khamlichi AA, Denoroy L, Spinelli S, Touchard G, Preud'homme JL, Cogné M. Monoclonal Ig L chain and L chain V domain fragment crystallization in myeloma-associated Fanconi's syndrome. *J Immunol*. 1993;150:3561-3568.
  57. Engle RL, Wallis LA. Multiple myeloma and the adult Fanconi syndrome. I. Report of a case with crystal-like deposits in the tumor cells and in the epithelial cells of the kidney. *Am J Med*. 1957;22:5-12. [https://doi.org/10.1016/0002-9343\(57\)90333-9](https://doi.org/10.1016/0002-9343(57)90333-9)
  58. Costanza DJ, Smoller M. Multiple myeloma with the Fanconi syndrome: study of a case, with electron microscopy of the kidney. *Am J Med*. 1963;34:125-133. [https://doi.org/10.1016/0002-9343\(63\)90046-9](https://doi.org/10.1016/0002-9343(63)90046-9)
  59. Deret S, Denoroy L, Lamarine M, Vidal R, Mougenot B, Frangione B, Stevens FJ, Ronco PM, Aucouturier P. Kappa light chain-associated Fanconi's syndrome: molecular analysis of monoclonal immunoglobulin light chains from patients with and without intracellular crystals. *Protein Eng* 1999; 12: 363-369. <https://doi.org/10.1093/protein/12.4.363>
  60. Messiaen T, Deret S, Mougenot B, Bridoux F, Dequiedt P, Dion JJ, Makkassi R, Meeus F, Pourrat J, Touchard G, Vanhille P, Zaoui P, Aucouturier P, Ronco PM: Adult Fanconi syndrome secondary to light chain gammopathy. Clinicopathologic heterogeneity and unusual features in 11 patients. *Medicine (Baltimore)* 2000; 79: 135-154. <https://doi.org/10.1097/00005792-200005000-00002>
  61. Rocca A, Khamlichi AA, Touchard G, Mougenot B, Ronco P, Denoroy L, Déret S, Preud'homme JL, Aucouturier P, Cogné M.

- Sequences of V kappa I subgroup light chains in Fanconi's syndrome. Light chain V region gene usage restriction and peculiarities in myeloma-associated Fanconi's syndrome. *J Immunol* 1995; 155: 3245-3252.
62. Leboulleux M, Lelongt B, Mougenot B, Touchard G, Makdassi R, Rocca A, Noël LH, Ronco P, Aucouturier P. Protease resistance and binding of Ig light chains in myeloma-associated tubulopathies. *Kidney Int.* 1995;48:72-79. <https://doi.org/10.1038/ki.1995.269>
63. Rao DS, Parfitt AM, Villanueva AR, Dorman PJ, Kleerekoper M. Hypophosphatemic osteomalacia and adult Fanconi syndrome due to light-chain nephropathy. Another form of oncogenous osteomalacia. *Am. J. Med.* 1987; 82:333-338. [https://doi.org/10.1016/0002-9343\(87\)90081-7](https://doi.org/10.1016/0002-9343(87)90081-7)
64. Clarke BL, Wynne AG, Wilson DM, Fitzpatrick LA. Osteomalacia associated with adult Fanconi's syndrome: clinical and diagnostic features. *Clin. Endocrinol.* 1995;43:479-490. <https://doi.org/10.1111/j.1365-2265.1995.tb02621.x>
65. Levine SB, Bernstein LD. Crystalline inclusions in multiple myeloma. *JAMA.* 1985;254:1985. <https://doi.org/10.1001/jama.1985.03360140143043>
66. DeFronzo RA, Cooke CR, Wright JR, Humphrey RL. Renal function in patients with multiple myeloma. *Medicine (Baltimore)* 1978; 57: 151-166. <https://doi.org/10.1097/00005792-197803000-00003>
67. Batuman V, Guan S, O'Donovan R, Puschett JB. Effect of myeloma light chains on phosphate and glucose transport in renal proximal tubule cells. *Ren Physiol Biochem* 1994; 17: 294-300 <https://doi.org/10.1159/000173861>
68. Batuman V, Sastrasinh M, Sastrasinh S. Light chain effects on alanine and glucose uptake by renal brush border membranes. *Kidney Int* 1986; 30: 662-665. <https://doi.org/10.1038/ki.1986.237>
69. Smithline N, Kassirer JP, Cohen JJ. Light-chain nephropathy. Renal tubular dysfunction associated with light-chain proteinuria. *N Engl J Med* 1976; 294: 71-74 <https://doi.org/10.1056/NEJM197601082940202>
70. Merlini G, Stone MJ. Dangerous small B-cell clones. *Blood* 108: 2520-2530, 2006 <https://doi.org/10.1182/blood-2006-03-001164>
71. Thorner PS, Bedard YC, Fernandes BJ. Lambda-light-chain nephropathy with Fanconi's syndrome. *Arch Pathol Lab Med* 1983; 107: 654-657
72. Terashima K, Takahashi K, Kojima M, Imai Y, Tsuchida S, Migita S, Ebina S, Itoh C. Kappa-type light chain crystal storage histiocytosis. *Acta Pathol Jpn.* 1978;28: 111-138. <https://doi.org/10.1111/j.1440-1827.1978.tb01254.x>
73. Lebeau A, Zeindl-Eberhart E, Muller EC, Müller-Höcker J, Jungblut PR, Emmerich B, Löhrs U. Generalized crystal-storing histiocytosis associated with monoclonal gammopathy: molecular analysis of a disorder with rapid clinical course and review of the literature. *Blood.* 2002;100: 1817-1827
74. Ma CX, Lacy MQ, Rompala JF, Dispenzieri A, Rajkumar SV, Greipp PR, Fonseca R, Kyle RA, Gertz MA. Acquired Fanconi syndrome is an indolent disorder in the absence of overt multiple myeloma. *Blood* 2004; 104(1): 40-42 <https://doi.org/10.1182/blood-2003-10-3400>
75. Alter BP. Fanconi anemia and the development of leukemia. *Best Practice & Research Clinical Haematology* 2014;27:214-221 <https://doi.org/10.1016/j.beha.2014.10.002>
76. Gavriatopoulou M, Terpos E, Kastritis E, Dimopoulos MA. Current treatments for renal failure due to multiple myeloma. *Expert Opin Pharmacother.* 2016;17:2165-2177. <https://doi.org/10.1080/14656566.2016.1236915>