



Case Report

Rhino-Orbital-Cerebral Mucormycosis after Allogeneic Hematopoietic Stem Cell Transplantation and Isavuconazole Therapeutic Drug Monitoring during Intestinal Graft versus Host Disease

Giacomo Andreani¹, Gianluca Fadda², Dario Gned³, Matteo Dragani¹, Giovanni Cavallo², Valentina Monticone², Alessandro Morotti¹, Marco De Gobbi¹, Angelo Guerrasio¹, Anna Maria Barbui⁴, Antonio D'Avolio⁵ and Daniela Cilloni¹.

¹ Department of Clinical and Biological Sciences, University of Turin, San Luigi Gonzaga Hospital, Orbassano, Turin, Italy.

² Department of Otolaryngology, San Luigi Gonzaga Hospital, Orbassano, Turin, Italy.

³ Department of Diagnostic Imaging, San Luigi Gonzaga Hospital, Orbassano, Turin, Italy.

⁴ Microbiology and Virology Unit, Azienda Ospedaliera Universitaria Città della Salute e della Scienza, Turin, Italy.

⁵ Department of Medical Sciences, Laboratory of Clinical Pharmacology and Pharmacogenetics, University of Turin, Amedeo di Savoia Hospital, Turin, Italy.

Competing interests: The authors declare no conflict of Interest.

Abstract. A diagnosis of rhino-orbital-cerebral mucormycosis was made in a 59-year-old man with a secondary acute myeloid leukemia a few days after hematopoietic stem cell transplantation.

Prompt treatment with combined antifungal therapy (liposomal amphotericin B and isavuconazole) followed by a procedure of endoscopic sinus surgery resulted in the resolution of the infection. Therapeutic drug monitoring of isavuconazole was performed during the year of treatment showing an increment of plasma concentrations in correspondence with the improvement of intestinal GvHD, thus suggesting that in this or similar conditions TDM for isavuconazole can be of value.

A literature review of cases of rhino-orbital-cerebral and rhino-cerebral mucormycosis in allogeneic hematopoietic stem cell transplant recipients was carried out.

Keywords: Rhino-orbital-cerebral mucormycosis; Isavuconazole; Liposomal amphotericin B; Therapeutic drug monitoring; Deferasirox.

Citation: Andreani G., Fadda G.L., Gned D., Dragani M., Cavallo G., Monticone V., Morotti A., De Gobbi M., Guerrasio A., Barbui A.M., D'Avolio A., Cilloni D. Rhino-orbital-cerebral mucormycosis after allogeneic hematopoietic stem cell transplantation and isavuconazole therapeutic drug monitoring during intestinal graft versus host disease. *Mediterr J Hematol Infect Dis* 2019, 11(1): e2019061, DOI: <http://dx.doi.org/10.4084/MJHID.2019.061>

Published: November 1, 2019

Received: July 12, 2019

Accepted: September 19, 2019

This is an Open Access article distributed under the terms of the Creative Commons Attribution License (<https://creativecommons.org/licenses/by-nc/4.0>), which permits unrestricted use, distribution, and reproduction in any medium, provided the original work is properly cited.

Correspondence to: Giacomo Andreani, Department of Clinical and Biological Sciences of the University of Turin, San Luigi Gonzaga Hospital, Regione Gonzole 10, 10043, Orbassano, Turin, Italy. Tel.: +39 011 9026305; fax: +39 011 9026963. E-mail: giacomo.andreani@unito.it ORCID ID: <https://orcid.org/0000-0003-4877-3929>

Introduction. Mucormycosis is an aggressive and potentially fatal invasive fungal infection which can manifest by a variety of different syndromes. The genera in the order of Mucorales most commonly

found in humans are *Rhizopus*, *Mucor*, *Rhizomucor*.¹ Fungal spores are ubiquitous in the atmosphere, but infection is a rare event. Predisposing risk factors include diabetes mellitus, hematologic malignancies,

solid organ transplantation and hematopoietic stem cell transplantation (HSCT), trauma, burns, iron overload and immunosuppressive therapies. After *Aspergillus*, Mucorales are the most common fungal pathogens affecting patients undergoing HSCT; rhino-orbital-cerebral mucormycosis (ROCM) is the most common type of mucormycosis defined as a fulminant infection involving nose, paranasal sinuses, orbits, and brain. Management of ROCM requires a combination of antifungal therapy, debridement of involved tissues and if possible elimination of predisposing conditions. Despite early diagnosis and aggressive treatment the prognosis is poor.²

Case Presentation. Here, we report the case of a 59-year-old man with acute myeloid leukemia (AML) arising in August 2017 from a 5q- myelodysplastic syndrome treated with lenalidomide. A Mito-FLAG induction scheme (G-CSF from day -1, fludarabine 60 mg/die days 1-5, cytarabine 2 g over 3 h every 12 h days 1-5, mitoxantrone 12 mg/die day 1, 3 and 5) followed by two cycles of consolidation chemotherapy were administered (Mito-FLAG again and one cycle with high-doses-cytarabine); meanwhile a donor search was started. In March 2018, after a TBF reduced-intensity conditioning regimen (thiotepa 390 mg day -6, busulfan 240 mg/die days -5 and -4; fludarabine 80 mg day -3) the patient underwent allogeneic HSCT from a matched unrelated donor. Miconazole was used for fungal prophylaxis. Rabbit-derived anti-thymocyte globulins infusion (2.5 mg/Kg days -3, -2, -1), cyclosporine A (3 mg/Kg, continuous infusion from day -1) and methotrexate (30 mg day +1 then 20 mg days +3 and +6) were administered for GvHD prophylaxis. Since the diagnosis of AML to HSCT a total of 47 units of red blood cells were transfused, deferasirox (an iron-chelating agent) was started two months before HSCT producing a ferritinemia reduction from 2713 to 1489 ng/ml few days before the beginning of conditioning regimen; deferasirox administration was stopped during the transplant procedure.

Day +1 from HSCT, the patient complained, on the right side of the face, a sharp pain mimicking trigeminal neuralgia and responsive to high doses of morphine. CT scan of brain and sinuses showed a picture of pansinusitis. At day +2, after a sudden onset of fever, empirical antibacterial therapy (piperacillin/tazobactam plus amikacin) and antifungal therapy with liposomal amphotericin B (L-Amb) were started. Diplopia occurred in day +6, a palsy of VI right cranial nerve was detected plus a sensitive deficit of V cranial nerve of the same side. Magnetic resonance imaging (MRI) of brain and sinuses plus MR angiography with contrast dye showed the presence of a mycetoma in the right sphenoidal sinus associated with thrombophlebitis of the cavernous sinus,

thrombosis of the superior ophthalmic vein and possible involvement of temporal meninges in contiguity with the bone cavity.

Blood indirect biomarkers for the detection of a fungal infection (1,3-beta-D-glucan and galactomannan) were negatives over the entire period. Antifungal therapy was reinforced, a combination of L-AmB at the dosage of 7.5 mg/Kg/die plus iv isavuconazole (ISC) 200 mg (375 mg of isavuconazonium sulfate equivalent to 200 mg of ISC) every 8 hours for six doses followed by 200 mg/die was started. Day +11, the patient, still in aplasia (WBC 10/mm³, Hb 7.0 g/dl, platelets 10000/mm³), underwent a procedure of endoscopic sinus surgery (ESS) after transfusions of blood components with no complications. The cultural and histological examination does not reveal presence of hyphae; *Rhizomucor* was identified by amplification and sequencing of two Internal Transcribed Spacer regions (ITS1 and ITS2) in *rRNA* gene. The Sanger sequencing was performed after amplification using ITS1-Forward and ITS4-reverse primers.³

The patient achieved myeloid engraftment at day +16 and became afebrile. The trigeminal neuralgia regressed although the VI right cranial nerve palsy persistence, antibiotics were stopped and the combined antifungal therapy was continued. A new MRI, at day +41, revealed the presence of a brain mycotic abscess with associated vasogenic cerebral edema of the right temporal lobe (**Figure 1**). Although the involvement of the cavernous sinus was detected, an excisional neurosurgery intervention of the cerebral abscess was not undertaken considering the procedural high-risk balanced to the benefits of an incomplete drainage. The patient was discharged, ISC was switched to oral formulation, and L-AmB was administered in an outpatient setting for 74 days in total. Cyclosporine administration was stopped one month after transplantation for fear to promote *Rhizomucor* growth and further dissemination. The general condition of the patient worsened; he lost 30 Kg of weight in total, parenteral nutrition was started. We were forced to introduce steroid therapy (prednisone 1 mg/Kg/die) for severe gastrointestinal, cutaneous and ocular GvHD. Because the response of cutaneous GvHD to steroids was not adequate, extracorporeal photoapheresis was started with benefit. Megestrol acetate, an orexigenic, was dispensed to treat cachexia. ISC dosage was increased to 300 mg/die in consideration of ISC plasma concentrations (**Figure 2**); deferasirox was reintroduced in therapy.

At six months from HSCT, a new MRI of the brain showed the reduction of the para-cavernous abscess with partial reabsorption of the purulent quote and temporal lobe edema (**Figure 1**). Complete thrombosis of the right internal carotid artery was detected but patient remained completely asymptomatic for it. We

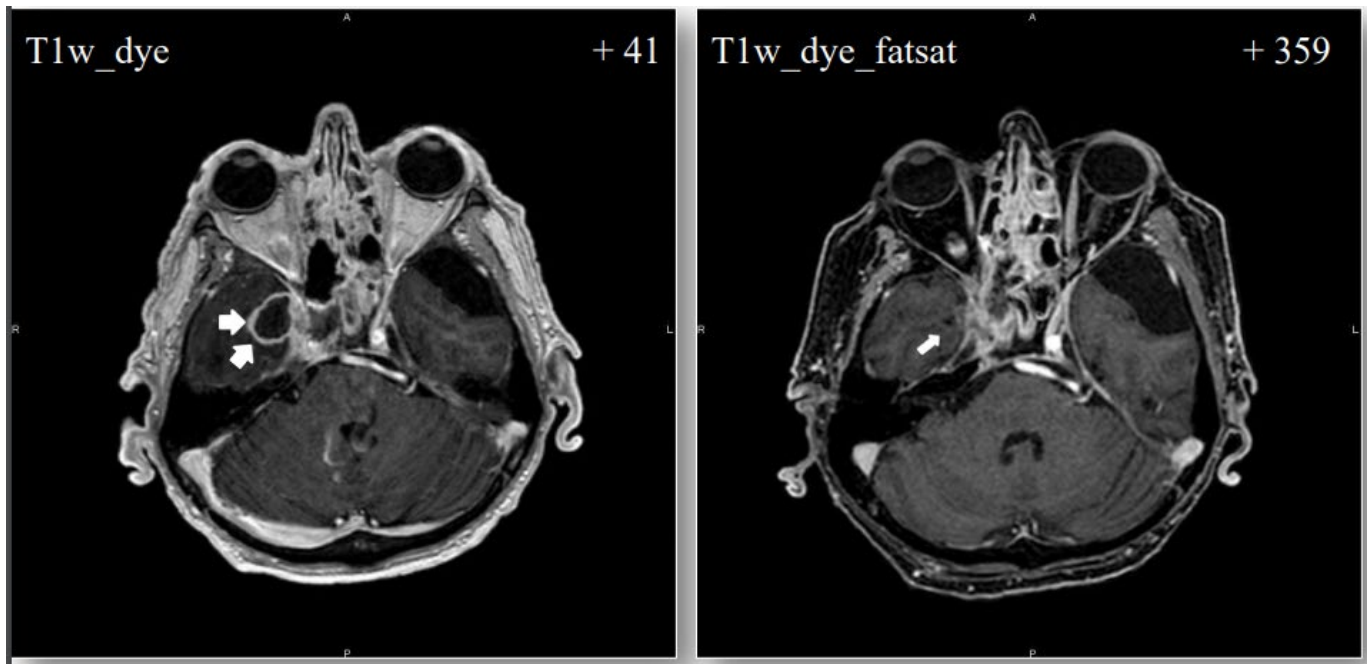


Figure 1. MRI images showing endocranial mycotic abscess at day 41 and the result at the end of treatment with ISC, day 359.

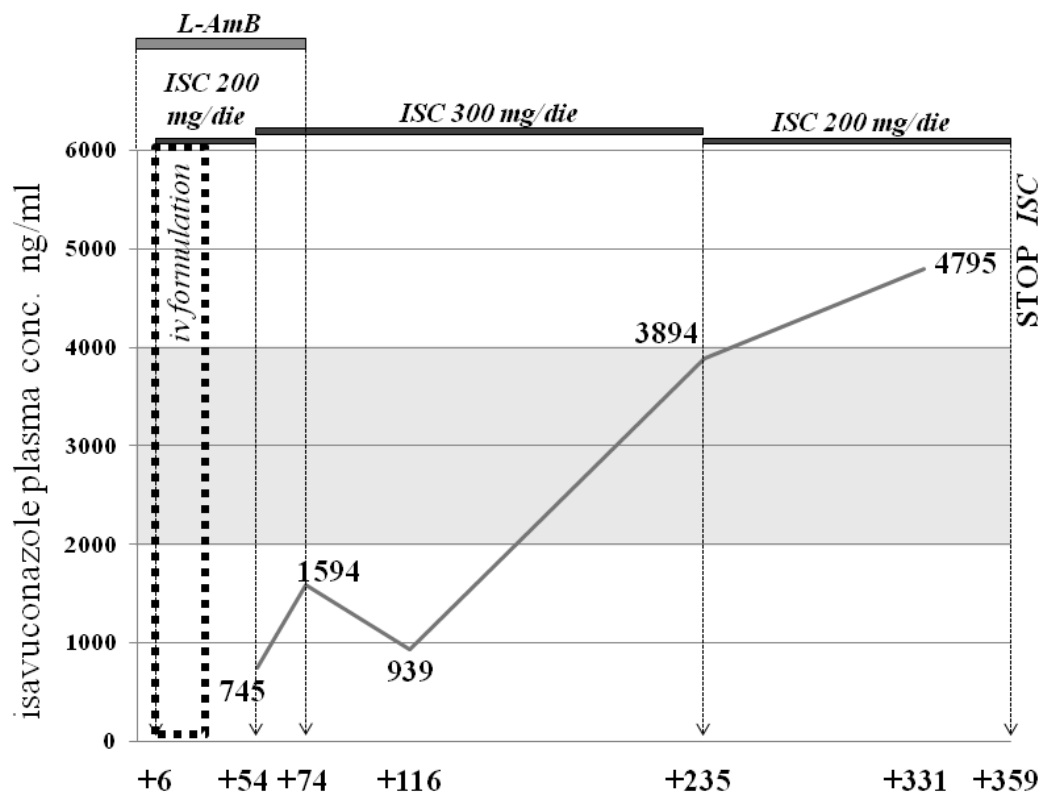


Figure 2. TDM of ISC during one year of treatment showing an increment of plasma concentrations in correspondence with the improvement of intestinal GvHD (all blood samples were collected 12 hours after the last administration of the drug).

decided to continue antifungal therapy with ISC at 300 mg/die then we reduced the dosage to 200 mg/die based on therapeutic drug monitoring (TDM).

Patient's mood improved and body weight with it, he started to have a complete meal and to walk again with crutches. Palsy of VI right cranial nerve regressed almost completely; prednisone was reduced and maintain to a dose of 10 mg/die for hepatic and

intestinal GvHD. Reevaluation of bone marrow at one year from HSCT confirmed full donor chimerism. Brain MRI revealed further reduction of the endocranial mycotic abscess (8 x 3 mm), no purulent quote was present. In accordance with clinical improvement we considered it a full response, and we decided to stop isavuconazole after 354 days of treatment.

Literature Review of Cases of Rhino-Orbital-Cerebral Mucormycosis in Allogeneic Hematopoietic Stem Cell Transplant Recipients. We searched all published journal articles in MEDLINE starting from 2005 with the search terms “Rhino-orbital-cerebral mucormycosis”, “Rhino-cerebral mucormycosis”, “Hematopoietic stem cell transplantation”. We included only case reports and case series of ROCM, or rhino-cerebral mucormycosis (RCM) in which infection was diagnosed during or after allogeneic HSCT, no other extensive reviews were included due to lack of information. We identified 5 cases in literature (3 ROCM and 2 RCM) (Table 1). The type of donors were: matched related donor (MRD) in 3 cases,^{4,6} a HLA (human leukocyte antigen) haploidentical donor in one case,⁷ and in another case a HLA-matched donor not otherwise specified;⁸ the underlying disease was AML in two cases, one case was a Ph+ B-ALL (B-cell acute lymphoblastic leukemia), one was a pre-B cell ALL (a 5-year-old boy) and another case was a T-cell prolymphocytic leukemia. The species in the order of Mucorales were different: two patients were infected by *Rhizopus oryzae*, one patient by *Cunninghamella bertholletiae*, another patient by *Lichthemia corymbifera*, in one case the species of *Mucor* was not mentioned. Fluconazole was used as fungal prophylaxis in three cases and voriconazole in one case; in another case the type of prophylaxis was not mentioned. MRI has been a fundamental tool in the suspicious of ROCM/RCM; the

diagnosis was performed by microscopy and culture after biopsy or surgery debridement in 4 cases, one of which also reported performance of the sequence analysis of ITS region; in one case data was not reported. In four cases single antifungal therapy with L-Amb was administered (two of them switched from caspofungin and posaconazole respectively), in one case double antifungal therapy with L-Amb plus posaconazole was administered. In three cases surgical debridement was performed. All patients deceased few days or weeks after the onset of the infection.

Discussion. The mortality rate of ROCM is reported being between 15% and 85% with worst prognosis for patients with brain, cavernous sinus, and carotid involvement.⁹ It is fundamental to rapidly start the management, any delay on the treatment results in an increase in mortality rate. The most common finding by CT scan of patients with ROCM is simple sinusitis, and a negative CT scan does not rule out mucormycosis. MRI is recommended because it is more sensitive for detecting orbital and central nervous system (CNS) involvement.¹⁰ In the clinical case reported above, the mycetoma appeared on MRI as an intrasinus mass hypointense on T2w and non-homogeneously hyperintense on T1w with a peripheral contrast enhancement due to inflammatory thickening of the surrounding mucosa; artifacts consistent with the presence of iron and manganese were detected in T2w*. Differential diagnosis with granulomatous sinusitis is

Table 1. Case series of ROCM or rhino-cerebral mucormycosis (RCM) in which infection was diagnosed during or after allogeneic HSCT.

Ref. (year)	Mucorales (genus-species)	Age/gender	Hematologic Malignancy/BMT (Timing of infection)	Donor Type	Diagnosis	Prophylaxis	Treatment	Surgery	Outcome (time from infection)
Righi (2007) ⁴ RCM	<i>Cunninghamella bertholletiae</i>	41/M	AML (I diagnosis after induction)/ re-occurrence of infection after BMT	MRD	MRI/biopsy	no data	Caspo then L-Amb (during consolidation and BMT)	Yes, after induction	Deceased (+7 days)
Abela (2013) ⁸ ROCM	<i>Lichthemia corymbifera</i>	5/M	pre-B cell ALL/ symptoms during conditioning regimen	HLA-matched (NOS)	MRI/deep nasal swab	Fluco	Post mortem diagnosis	No	Deceased (+8 days)
Strasfeld (2013) ⁵ ROCM	Mucor NOS	59/F	T-PLL/salvage alemtuzumab/ diagnosis +245 days from BMT	MRD	no data	Fluco	L-Amb + Posa	Yes	Deceased (+18 days)
Shigemura (2015) ⁷ ROCM	<i>Rhizopus oryzae</i>	27/F	AML/ diagnosis at relapse (seven months from second BMT)	Haplo (mother)	MRI/biopsy and ITS analysis/ (serum DNA load)	Vorico	L-Amb	No	Deceased (+12 days)
Shumilov (2018) ⁶ RCM	<i>Rhizopus oryzae</i>	45/M	B-ALL Ph+/ diagnosis 5 months after BMT	MRD	MRI/biopsy/ (IHC)	Fluco	Posa then L-Amb	Yes	Deceased (+5 months)
Andreani (2019) - ROCM	Rhizomucor NOS	59/M	AML (>MDS)/ symptoms from day +1 after BMT	MUD	MRI/ surgery and ITS analysis	Mica	L-Amb + ISC	Yes	Resolution (alive at 15 months)

ALL, acute lymphoblastic leukemia; AML, acute myeloid leukemia; BMT, bone marrow transplantation; Caspo, caspofungin; Fluco, fluconazole; Haplo, haploidentical donor; HLA, human leukocyte antigen; IHC, immunohistochemistry; L-Amb, liposomal amphotericin B; MRD, matched related donor; MRI, magnetic resonance; MUD, matched unrelated donor; NOS, not otherwise specified; Posa, posaconazole; RCM, rhino-cerebral mucormycosis; ROCM, rhino-orbital-cerebral mucormycosis; T-PLL, T-cell prolymphocytic leukemia; Vorico, voriconazole.

difficult on MRI; conversely a contrast enhancement of the mass is more suspicious for the presence of a squamous cell carcinoma or lymphoma of the sinus. Finally, mucocele can be quite easily distinguished, among other things, for its hyperintensity on T2w on MRI.

Serum test, 1,3-beta-D-glucan assay, and galactomannan assay are not useful in patients suspected of having mucormycosis because Mucorales do not have these components on cell wall. Identification of the pathogen most often comes from microscopy, culture, histopathological examination and/or sequencing of specific DNA regions on biopsy samples but it is essential to know that no more than 50% of cases are diagnosed by combined histopathology and culture; molecular techniques are intriguing and increasingly used methods that can be rapidly performed, on different samples (for instance on blood), in the suspicious and/or in the monitoring of the infection with less or no procedural risks for patients.³

Optimal therapy requires a multidisciplinary approach consisting on a prompt antifungal therapy, reversal of underlying predisposing conditions (whenever possible, e.g. severe neutropenia) and surgical debridement is recommended, when feasible.¹¹ The use of deferasirox in mucormycosis is debated: it has been demonstrated that deferasirox, contrary to deferoxamine, do not act as siderophore for Mucorales indeed it has a fungicidal effect;¹² the result of higher mortality rate at 90 days in the group of deferasirox plus L-AmB compared to L-AmB alone in a very small (n= 20) prospective, double-blind, placebo-controlled trial of hematologic patients appears very difficult to interpret because of important imbalanced characteristics between two treatment groups.¹³ To sum up we suggest to introduce deferasirox in mucormycosis treatment as soon as possible; this is what we did with our patient. Moreover, we administered iron chelator few weeks before transplantation to reduce high levels of ferritinemia due to several blood transfusions, despite this we consider iron overload in our patient as one of the major culprits of the early onset of the infection after HSCT, together with the condition of aplasia and immunosuppression.

Concerning antifungal therapy *tout-court*, we initially adopted a combined treatment with L-AmB and ISC, followed by a prompt surgical debridement. Next we stepped down therapy to ISC only, because of

patient inability to attend daily the outpatient clinic (Italian National Health Service does not allow L-Amb administration in a home setting therapy). ISC is a broad-spectrum azole drug with activity against yeasts, mould and dimorphic fungi, and it has been approved by FDA as first-line treatment for mucormycosis and by EMA in cases in which L-AmB is inappropriate.¹⁴ Considering the condition of profound immunosuppression of our patient and in light of CNS involvement we opted for a combined antifungal therapy *ab initio*, as already reported from other groups.¹⁵ Although many works declare no apparent relationship between exposure and efficacy to suggest routine TDM for ISC, the same raise the issue for patients with intestinal GvHD in which drug absorption through the oral route can be decreased and in cases of CNS involvement.¹⁶ In our patient ISC plasma concentrations after switch to oral formulation were below expected range of values, 2000-4000 ng/ml considering ISC Minimum Inhibitory Concentrations for *Rhizomucor* from previous studies¹⁷ (ISC plasma concentrations were assessed by an HPLC/GC-mass spectrometry assay),¹⁸ coinciding with a severe intestinal GvHD so we opted for an increment in dosage to 300 mg/die. However, ISC plasma concentrations grew up dramatically only after improvement of intestinal GvHD although the reduction in ISC dosage. A recently published work assessing ISC plasma concentration in 19 patients with hematologic malignancies (six of them previously undergone allogeneic HSCT) retrospectively observed an increment in ISC concentration overtime during treatment, authors speculate that the increasing trend could be due to expected drug accumulation in tissues and consequently in plasma.¹⁹ Regardless of different possible explanations we can formulate for the trend of TDM, it is crucial to identify ISC efficacy concentration thresholds. The aim is to pursue a correct dose adjustment in those patients, like HSCT recipients, in whom intestinal absorption is reduced and in whom concomitant medications can modify ISC concentrations.²⁰ In lack of defined thresholds we believe that in this hematologic setting of large interpatient pharmacokinetic variability, TDM of ISC can be a tool of value to sustain clinician in the decision-making giving the possibility to compare drug exposure of the patient to results that came out from clinical trials and to those they are coming out on real-world practice.

References:

1. Vaughan C, Bartolo A, Vallabh N, Leong SC. A meta-analysis of survival factors in rhino-orbital-cerebral mucormycosis - has anything changed in the past 20 years? *Clinical Otolaryngology*. 2018;43:1454-1464. <https://doi.org/10.1111/coa.13175> PMID:29947167
2. Jeong W, Keighley C, Wolfe R, et al. The epidemiology and clinical manifestations of mucormycosis: a systematic review and meta-analysis of case reports. *Clin Microbiol Infect*. 2019;25(1):26-34. <https://doi.org/10.1016/j.cmi.2018.07.011> PMID:30036666

3. Korabecna M. The Variability in the Fungal Ribosomal DNA (ITS1, ITS2, and 5.8 rRNA Gene): Its Biological Meaning and Application in Medical Mycology. In *Communicating Current Research and Educational Topics and Trends in Applied Microbiology*; Mendez-Vilas, A., Ed.; Formatex: Badajoz, Spain, 2007; pp. 783-787.
4. Righi E, Giacomazzi CG, Lindstrom V, et al. A Case of *Cunninghamella bertholletiae* Rhino-cerebral Infection in a Leukemic Patient and Review of Recent Published Studies. *Mycopathologia*. 2018;165:407-410. <https://doi.org/10.1007/s11046-008-9098-z> PMID:18340546
5. Strasfeld L, Espinosa-Aguilar L, Gajewski JL et al. Emergence of *Cunninghamella* As a Pathogenic Invasive Mold Infection in Allogeneic Transplant Recipients. *Clin Lymphoma Myeloma Leuk*. 2013;13:622-8. <https://doi.org/10.1016/j.clml.2013.05.002> PMID:23850285
6. Shumilov E, Bacher U, Perske C, et al. In Situ Validation of the Endothelial Cell Receptor GRP78 in a Case of Rhinocerebral Mucormycosis. *Antimicrob Agents Chemother*. 2018;62(5). <https://doi.org/10.1128/AAC.00172-18> PMID:29483124
7. Shigemura T, Nishina S, Nakazawa H, et al. Early detection of *Rhizopus* DNA in the serum of a patient with rhino-orbital-cerebral mucormycosis following allogeneic hematopoietic stem cell transplantation. *Int J Hematol*. 2016;103:354-355. <https://doi.org/10.1007/s12185-016-1938-x> PMID:26781616
8. Abela L, Toelle SP, Hackenberg A, et al. Fatal outcome of rhino-orbital-cerebral mucormycosis due to bilateral internal carotid occlusion in a child after hematopoietic stem cell transplantation. *Pediatr Infect Dis J*. 2013;32(10):1149-50. <https://doi.org/10.1097/INF.0b013e31829e69e7> PMID:24067555
9. Roden MM, Zaoutis TE, Buchanan WL, et al. Epidemiology and outcome of zygomyces: a review of 929 reported cases. *Clin Infect Dis*. 2005;41:634-53. <https://doi.org/10.1086/432579> PMID:16080086
10. Spellberg B, Ibrahim AS. Recent Advances in the Treatment of Mucormycosis. *Curr Infect Dis Rep*. 2010; 12:423-429. <https://doi.org/10.1007/s11908-010-0129-9> PMID:21308550
11. Gamaletsou MN, Sipsas NV, Roilides E, Walsh TJ. Rhino-Orbital-Cerebral Mucormycosis. *Curr Infect Dis Rep*. 2012;14:423-434. <https://doi.org/10.1007/s11908-012-0272-6> PMID:22684277
12. Spellberg B, Andes D, Perez M, et al. Safety and outcomes of open-label deferasirox iron chelation therapy for mucormycosis. *Antimicrob Agents Chemother*. 2009;53:3122-3125. <https://doi.org/10.1128/AAC.00361-09> PMID:19433555
13. Spellberg B, Ibrahim AS, Chin-Hong PV, et al. The Deferasirox-AmBisome Therapy for Mucormycosis (DEFEAT Mucor) study: a randomized, double-blinded, placebo-controlled trial. *J Antimicrob Chemother*. 2012; 67: 715-722. <https://doi.org/10.1093/jac/dkr375> PMID:21937481
14. Maertens JA, Raad II, Marr KA et al. Isavuconazole versus voriconazole for primary treatment of invasive mould disease caused by *Aspergillus* and other filamentous fungi (SECURE): a phase 3, randomised-controlled, non-inferiority trial. *Lancet*. 2016;387:760-69. [https://doi.org/10.1016/S0140-6736\(15\)01159-9](https://doi.org/10.1016/S0140-6736(15)01159-9) PMID:26684607
15. Candoni A, Klimko N, Busca A, et al.; on behalf of SEIFEM Group (Epidemiological Surveillance of Infections in Haematological Diseases). Fungal infections of the central nervous system and paranasal sinuses in onco-haematologic patients. Epidemiological study reporting the diagnostic-therapeutic approach and outcome in 89 cases. *Mycoses*. 2019;62:252-260. <https://doi.org/10.1111/myc.12884> PMID:30565742
16. Stott KE, Hope WW. Therapeutic drug monitoring for invasive mould infections and disease: pharmacokinetic and pharmacodynamic considerations. *J Antimicrob Chemoter*. 2017;72 Suppl 1: i12-i18. <https://doi.org/10.1093/jac/dkx029> PMID:28355463
17. Rybak JM, Marx KR, Nishimoto AT, Rogers PD. Isavuconazole: Pharmacology, Pharmacodynamics, and Current Clinical Experience with a New Triazole Antifungal Agent. *Pharmacotherapy*. 2015;35(11):1037-1051. <https://doi.org/10.1002/phar.1652> PMID:26598096
18. Fatiguso G, Favata F, Zedda I, et al. A simple high performance liquid chromatography-mass spectrometry method for Therapeutic Drug Monitoring of isavuconazole and four other antifungal drugs in human plasma samples. *J Pharm Biomed Anal*. 2017;145:718.724. <http://doi.org/10.1016/j.jpba.2017.07.040> PMID:28806568
19. Furfaro E, Signori A, Di Grazia C, et al. Serial monitoring of isavuconazole blood levels during prolonged antifungal therapy. *J Antimicrob Chemother*. 2019;74(8):2341-2346. <http://doi.org/10.1093/jac/dkz188> PMID:31119272
20. Andes D, Kovanda L, Desai A, et al. Isavuconazole Concentration in Real-World Practice: Consistently with Results from Clinical Trials. *Antimicrob Agents Chemother*. 2018;62(7). <https://doi.org/10.1128/AAC.00585-18> PMID:29735569